


OMT Over Opioids

Osteopathic Manipulative Treatment in the Urgent Care Setting

Presented by **Michael Conte, D.O.**

Assistant Professor of Osteopathic Principles and Practices

October 25, 2019



Disclosures

- I have no financial disclosures or known conflicts of interest related to this presentation.

Objectives

- Identify common patient presentations in the urgent care setting where OMT may be used for treatment.
- Demonstrate OMT techniques that can be applied to the treatment of patients in the urgent care setting.
- Discuss potential pitfalls and contraindications to the use of OMT in the urgent care setting.

Urgent Care Obstacles

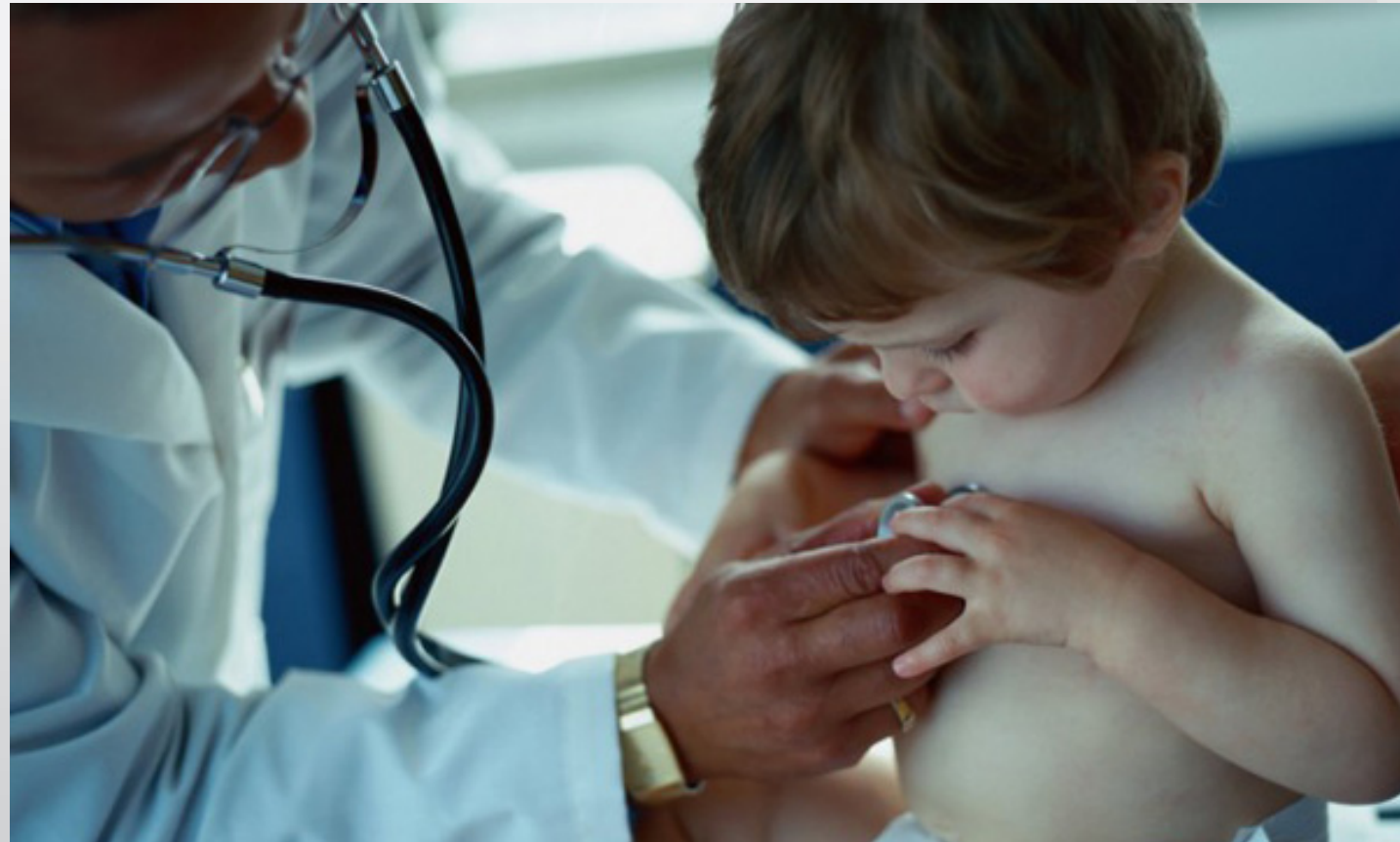- Limited patient history
- Limited specialty services
- Lack of rapport
 - Drug-seeking
 - Physician-Patient trust



The Osteopathic Advantage

Your D.O. training

- Holistic history-taking
- Osteopathic palpatory skills & structural exam
- Osteopathic Manipulative Treatment



Finding It

ICD-10: M99.0x - Segmental and Somatic Dysfunction

- M99.00 – ...of head region
- M99.01 – ...of cervical region
- M99.02 – ...of thoracic region
- M99.03 – ...of lumbar region
- M99.04 – ...of sacral region
- M99.05 – ...of pelvic region
- M99.06 – ...of lower extremity
- M99.07 – ...of upper extremity
- M99.08 – ...of rib cage
- M99.09 – ...of abdomen and other regions

Fixing It

CPT: Osteopathic Manipulative Treatment Procedures

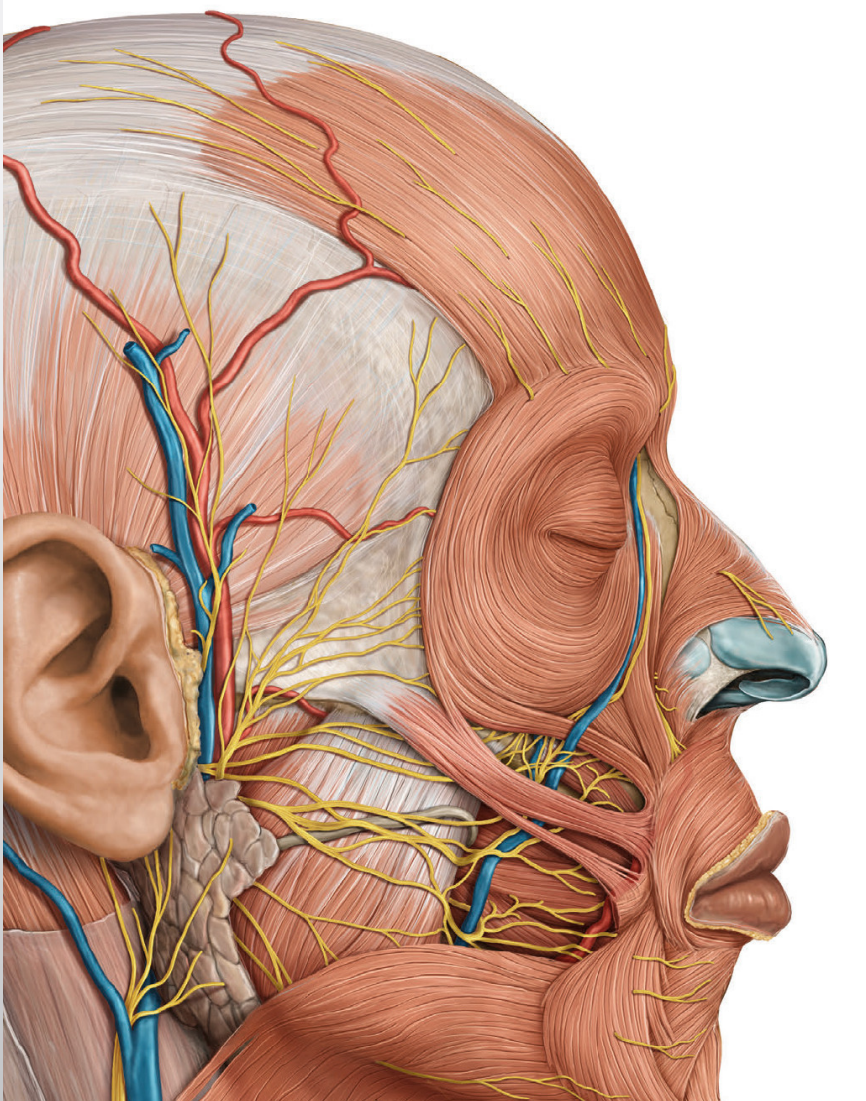
- 98925 – 1 to 2 body regions treated with OMT
- 98926 – 3 to 4 body regions treated with OMT
- 98927 – 5 to 6 body regions treated with OMT
- 98928 – 7 to 8 body regions treated with OMT
- 98929 – 9 to 10 body regions treated with OMT
- Don't forget to add the “-25” modifier to the E/M service code when both E/M service and OMT are performed on the same day of service

Document It

OMT Procedure Note

- OMT is a procedure
- Must have an ICD-10 code for somatic dysfunction documented, as this is the indication for the use of OMT.
- Document the following in a procedure note:
 - informed consent (risks, benefits, alternatives) obtained
 - regions manipulated
 - techniques used
 - patient response to treatment
- “Documenting in this fashion meets the requirements for billing out any procedure that is performed and assists in an audit situation when OMT is being challenged from a documentation perspective.”

Headache

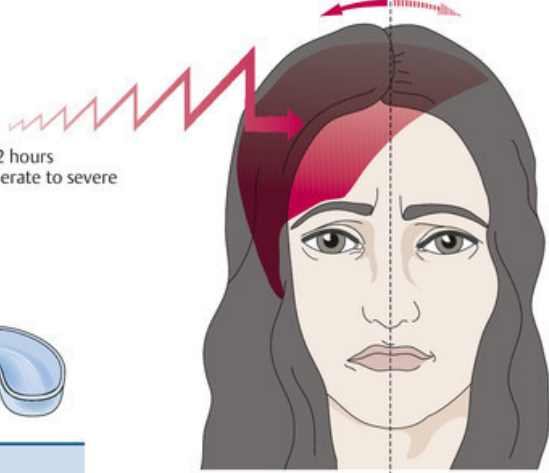


- Acute or sub-acute
- Generalized, perhaps occipital or “band-like” around the head
- Office worker (computer), machinist/assembly-line worker (holding positions for a long time with/without repetitive motion), construction (heavy lifting)
- Job-related stressors or stress at home

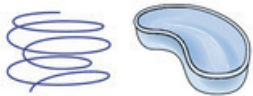
Maximum in 1-2 hours



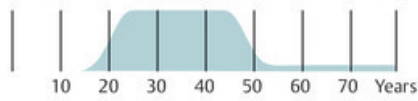
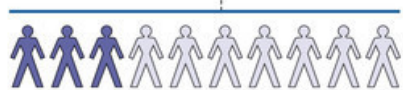
Duration: 4-72 hours
Intensity: moderate to severe



Aura
Photophobia
Nausea



	June				July				Interval: days to months
S	4	11	18	25	2	9	16	23	
M	5	12	19	26	3	10	17	24	31
T	6	13	20	27	4	11	18	25	
W	7	14	21	28	5	12	19	26	
T	1	8	15	22	6	13	20	27	
F	2	9	16	23	7	14	21	28	
S	3	10	17	24	8	15	22	29	

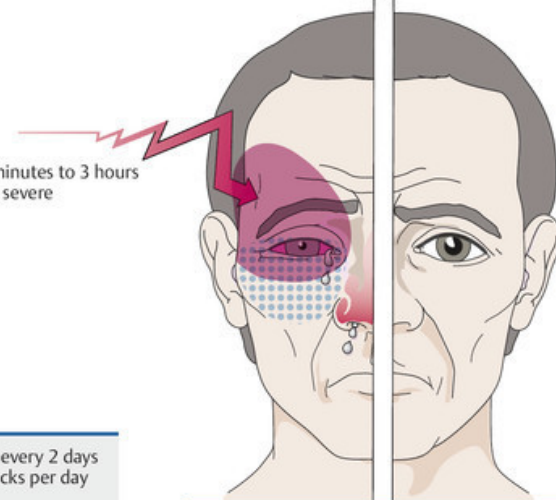


← Migraine


Maximum within 20 minutes



Duration: 15 minutes to 3 hours
Intensity: very severe

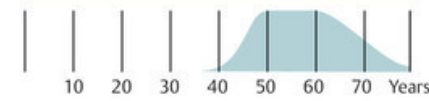
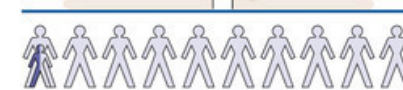

Cluster →



1 attack every 2 days
to 8 attacks per day

Often at night
Always at the
same time



PRIMARY HEADACHES

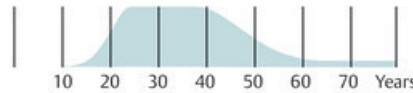
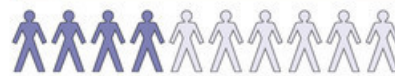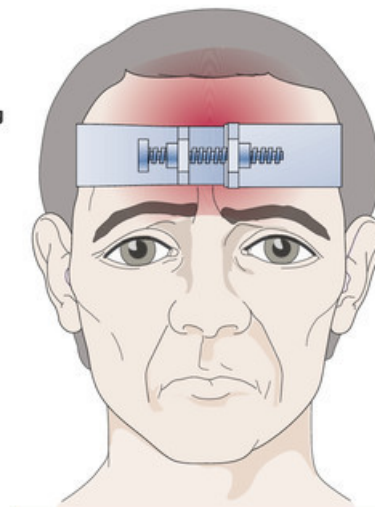

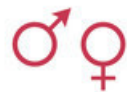
Usually beginning in the morning

Duration: 30 minutes to 7 days
Intensity: mild to moderate
Chronic: ≥ 15 attacks/month
Episodic: < 15 attacks/month

Chronic		June				July				
S		4	11	18	25	2	9	16	23	30
M		5	12	19	26	3	10	17	24	31
T		6	13	20	27	4	11	18	25	
W		7	14	21	28	5	12	19	26	
T		1	8	15	22	6	13	20	27	
F		2	9	16	23	7	14	21	28	
S		3	10	17	24	8	15	22	29	

Episodic		June				July				
S		4	11	18	25	2	9	16	23	30
M		5	12	19	26	3	10	17	24	31
T		6	13	20	27	4	11	18	25	
W		7	14	21	28	5	12	19	26	
T		1	8	15	22	6	13	20	27	
F		2	9	16	23	7	14	21	28	
S		3	10	17	24	8	15	22	29	



← Tension-type

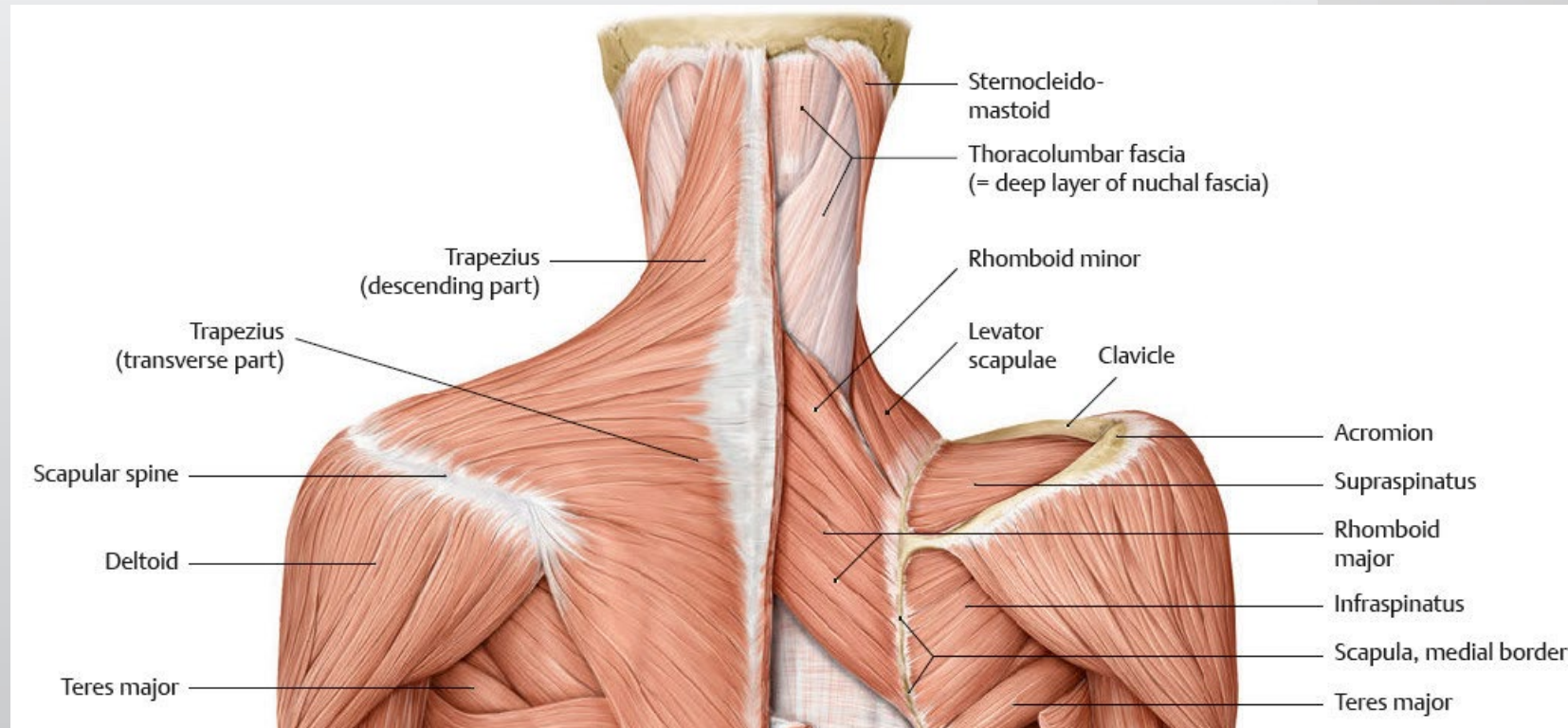
Headache

Potential pitfalls in the urgent care setting

- More severe pathology
 - Identify/rule out red flags
 - Sudden-onset, severe (“worst headache ever”) → SAH
- Time constraints
 - Problem: It takes extra time to perform an OSE
 - Solution: Make it a point to look for **TART** findings (Tissue texture abnormalities, Asymmetry, Restriction of motion, Tenderness) and document them in the record. Eventually it will become integrated into your physical exam procedure.

Headache

- If no red flags present, move on to Osteopathic Structural Exam (OSE)
 - Head region: occipito-atlantal joint, cranial strains
 - Cervical region: articular, muscular, soft tissue
 - Upper extremity: levator scapulae, upper trapezius
- Billing/Coding note:
 - Some structures span multiple body regions
Examples: trapezius, SCM, psoas
 - Be consistent with categorization



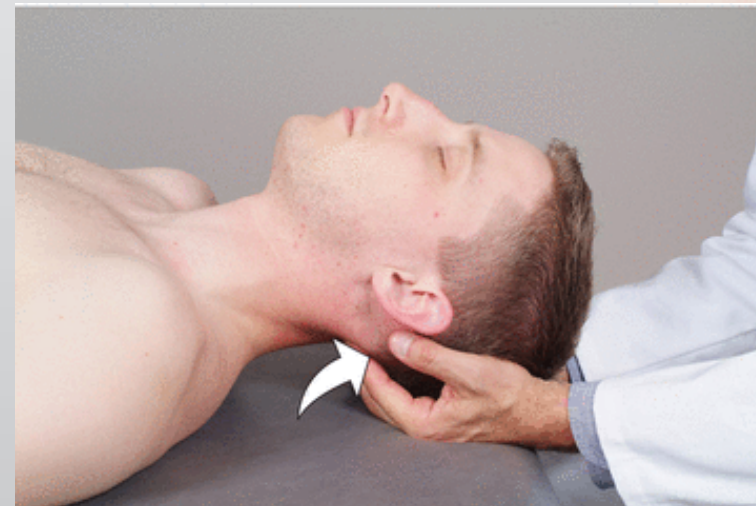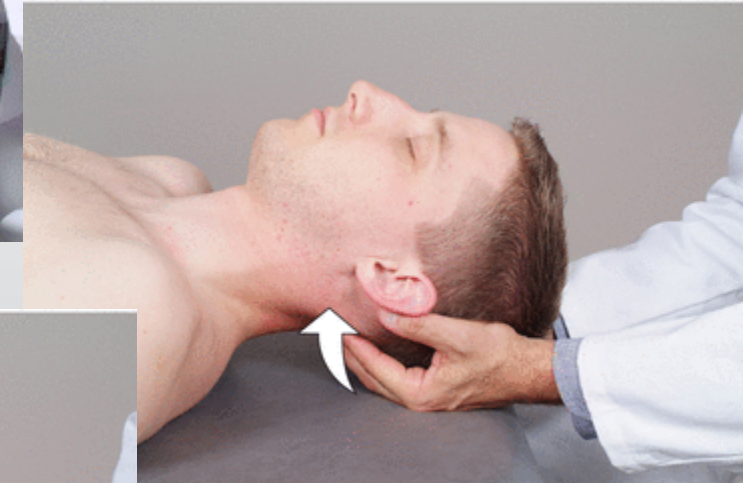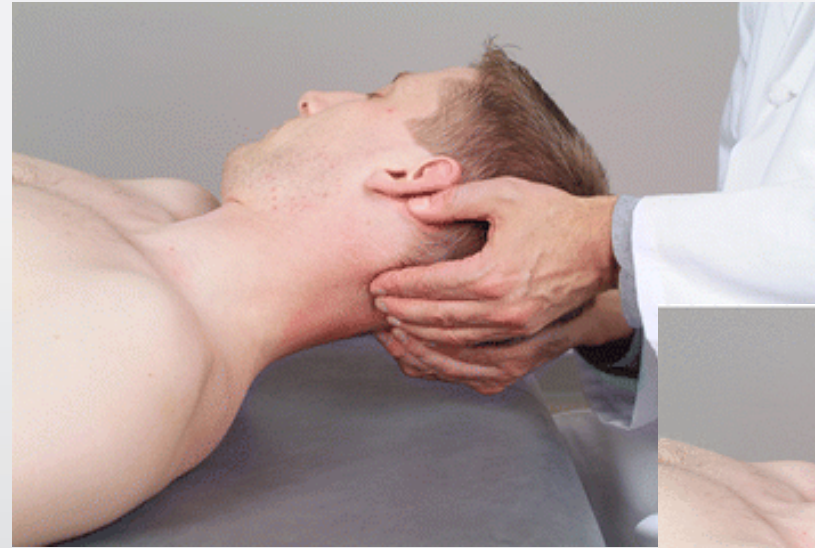Headache

Suboccipital Release

Supine, Intermittent/Inhibitory Method

1. Patient supine, DO sits at head of table.
2. DO's finger pads placed palm up beneath patient's suboccipital region, in contact with trapezius & immediate underlying musculature.
3. DO slowly & gently applies pressure upward into tissues for a few seconds, then releases.
4. This pressure may be reapplied & released slowly and rhythmically until tissue texture changes occur *or* for 2 minutes. Pressure may also be continued in a more constant inhibitory style for 30 seconds to 1 minute.

Modification: Position patient's head at the foot of the exam table (deploying table extension if needed).

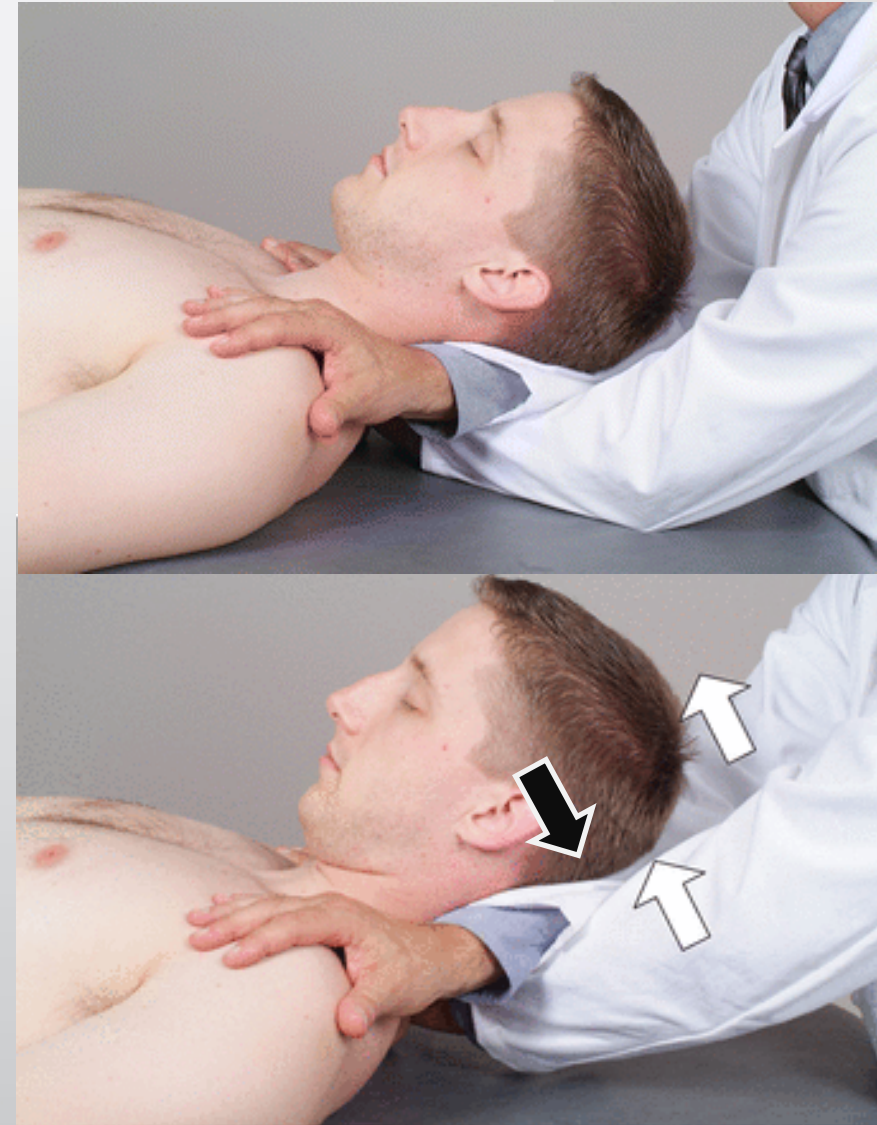


Headache

Regional (Long) Restrictor

Bilateral Forearm Fulcrum, Forward Bending Method
Post-Isometric Relaxation

1. Patient supine, DO sits at the head of table.
2. DO's arms crossed under patient's head, palms facing down onto patient's anterior shoulder region.
3. DO's forearms gently flex patient's neck (producing longitudinal stretch of the cervical paravertebral musculature) to edge of restrictive barrier.
4. DO instructs patient to extend or backward bend head & neck while DO applies an equal counterforce.
5. Hold isometric contraction 3 to 5 seconds, then instruct patient to *stop and relax*.
6. Once patient has completely relaxed, DO gently flexes neck to edge of new restrictive barrier.
7. Steps 4 to 6 repeated three to five times or until motion maximally improved.
8. Retest cervical range of motion to determine technique effectiveness.

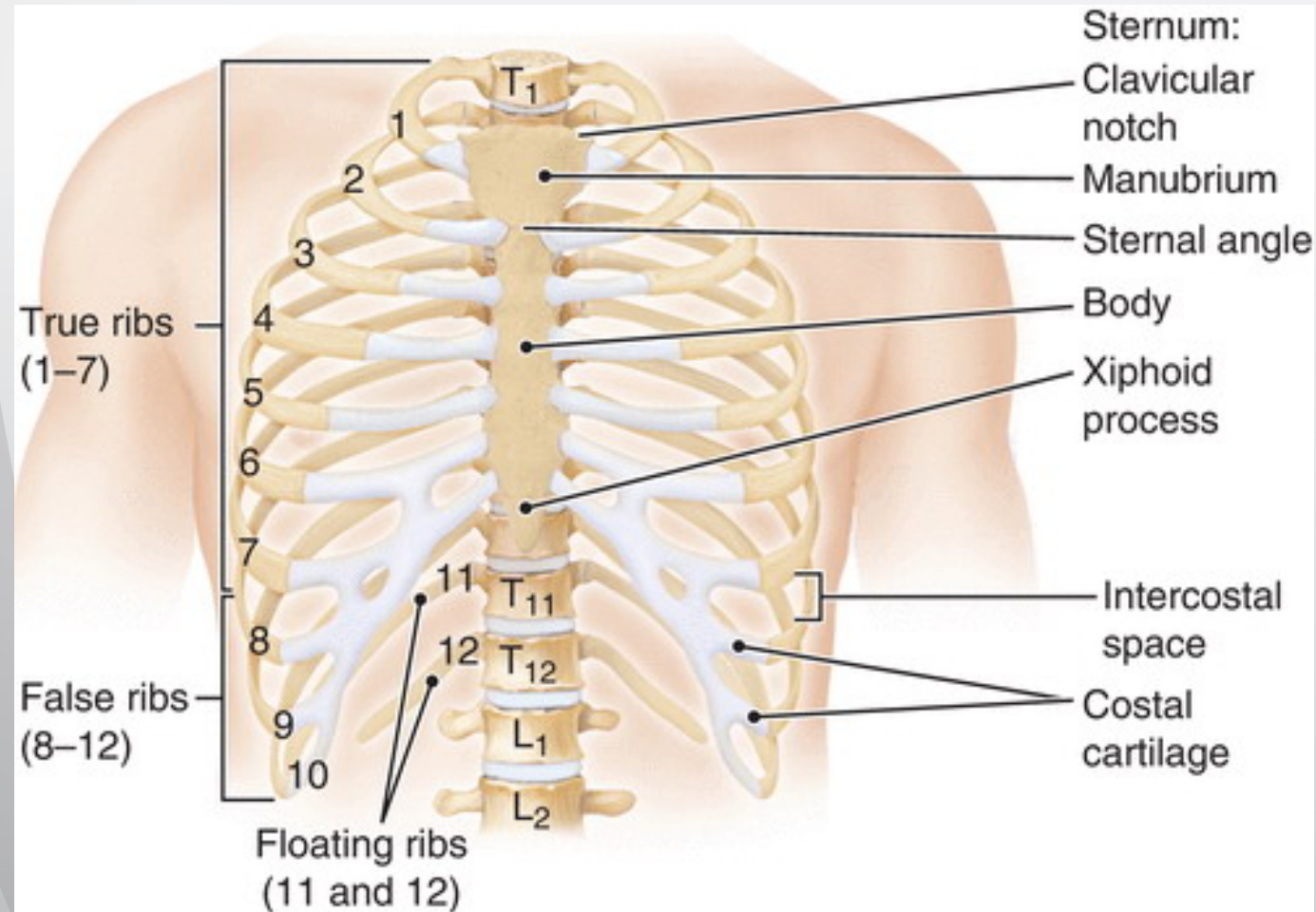


Headache

Contraindications to OMT

- Relative:
 - Neurologic or vascular compromise
 - Malignancy (local to area, lymphatic involvement)
 - Acute (moderate to severe) sprain or strain [MET]
 - Severe osteoporosis/-penia (DO believes risk of tendinous evulsion occurring with correction) [MET]
 - Infection (e.g. osteomyelitis), contagious skin disease, painful rashes/abscesses, acute fasciitis, any other conditions that would preclude skin contact; severe illness (i.e. postsurgical/ICU patient) [MET]
- Absolute:
 - Fracture, dislocation, or moderate to severe joint instability at treatment site [MET]
 - Lack of patient cooperation/comprehension of the instructions of the technique (i.e., infant or young child or patient who does not understand the physician's language) [MET]
 - Patient refusal of treatment (at any time)

Rib Pain



- Acute, sharp pain
- Pain anterior, lateral or posterior rib aspect
- Began after coughing, associated with URI/flu
- Pain worse with deep breathing

Rib Pain

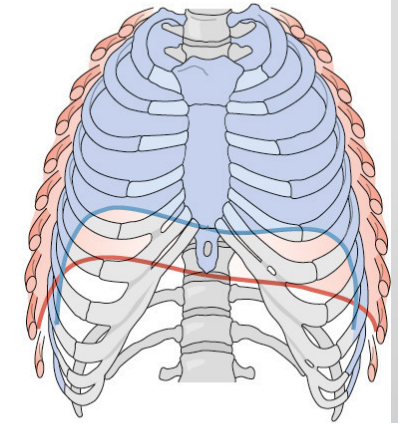
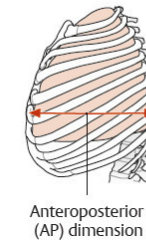
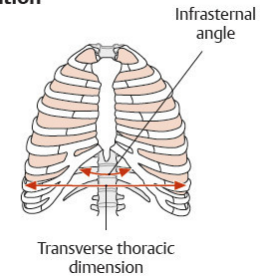
Potential pitfalls in the urgent care setting

- More severe pathology
 - Identify/rule out red flags
 - Fall or trauma; palpable disruption in rib contours → fracture
 - Hemoptysis → malignancy, TB
 - Non-reproducible on palpation & crackles on lung auscultation → pneumonia
 - Dermatomal, vesicular rash → Herpes zoster (shingles)
- Time constraints
 - Problem: It takes time to explain the procedure (OMT) to patients
 - Solution: While obtaining the patient history, inquire about previous manual therapies (e.g. OMT, chiropractic, massage, physical therapy, etc.). Any experience they have with these modalities can serve as a bridge to OMT to shorten the time needed for explanation.

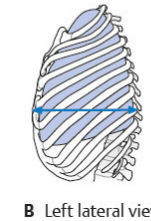
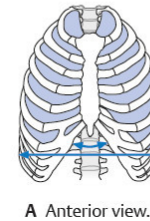
Rib Pain

- If no red flags present, move on to Osteopathic Structural Exam (OSE)
 - Rib cage: motion evaluation (pump handle, bucket handle, caliper), palpatory exam
 - Thoracic region: articular, muscular, soft tissue; viscerosomatic reflexes
 - Respiratory diaphragm: test phases of respiration

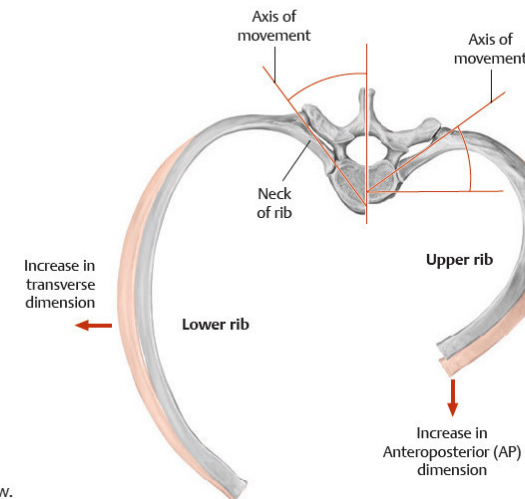
Inspiration



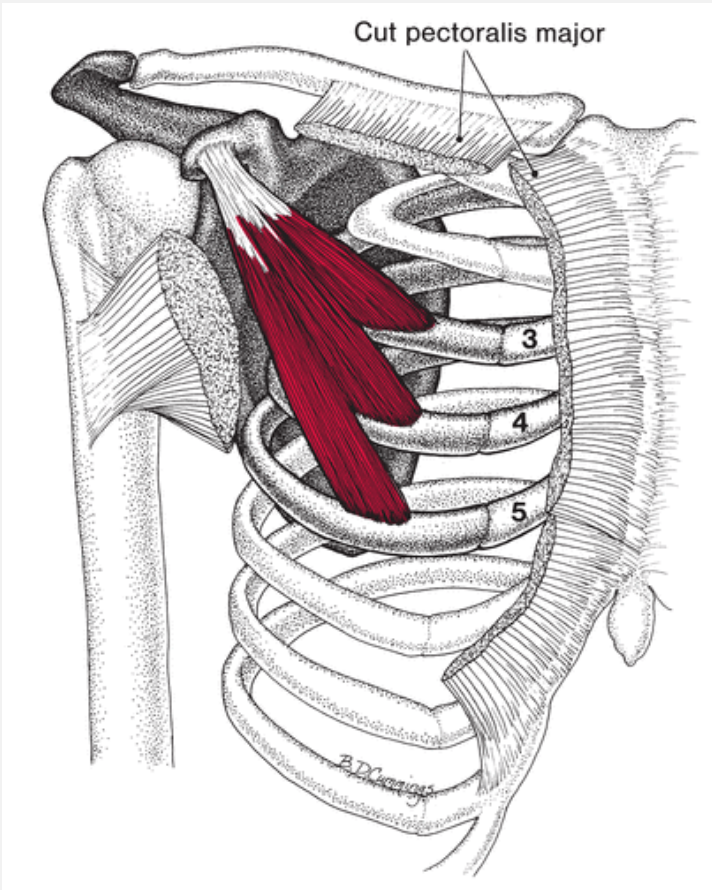
Expiration



C Position of diaphragm during respiration.

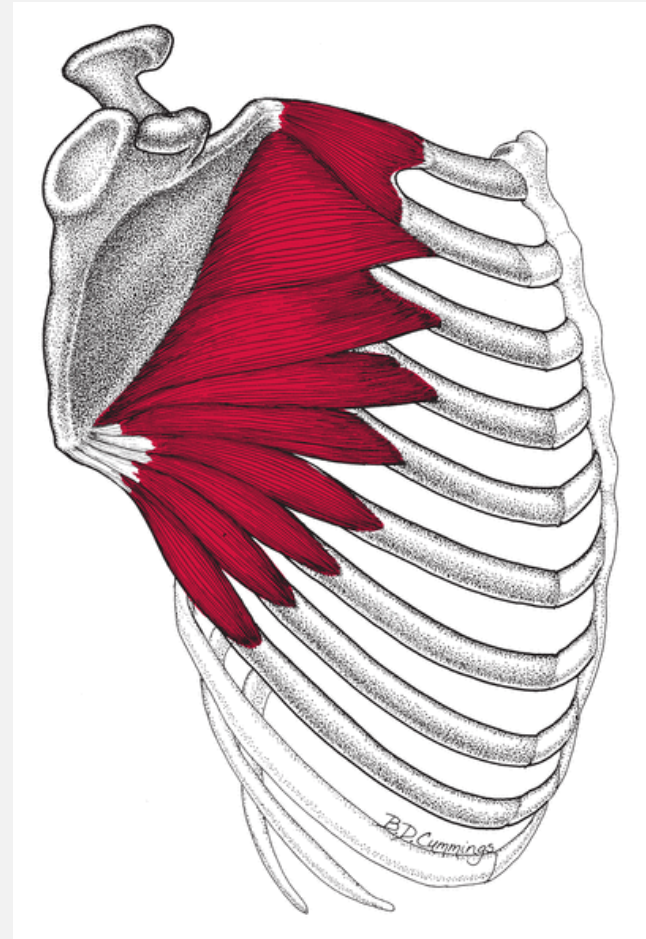


D Axes of rib movement, superior view.

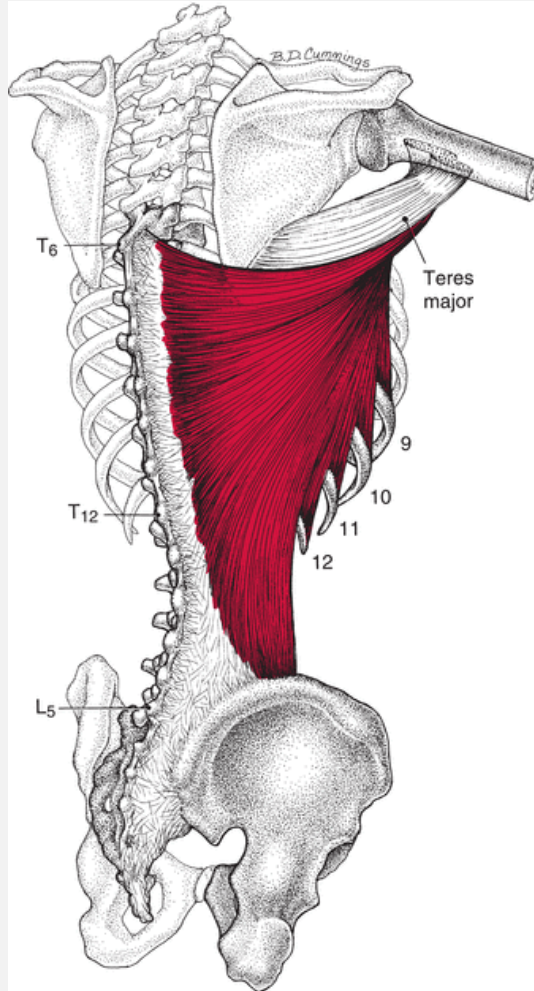


← Pectoralis minor

Serratus anterior →



RIB CAGE - MUSCULATURE



← Latissimus dorsi

Rib Pain

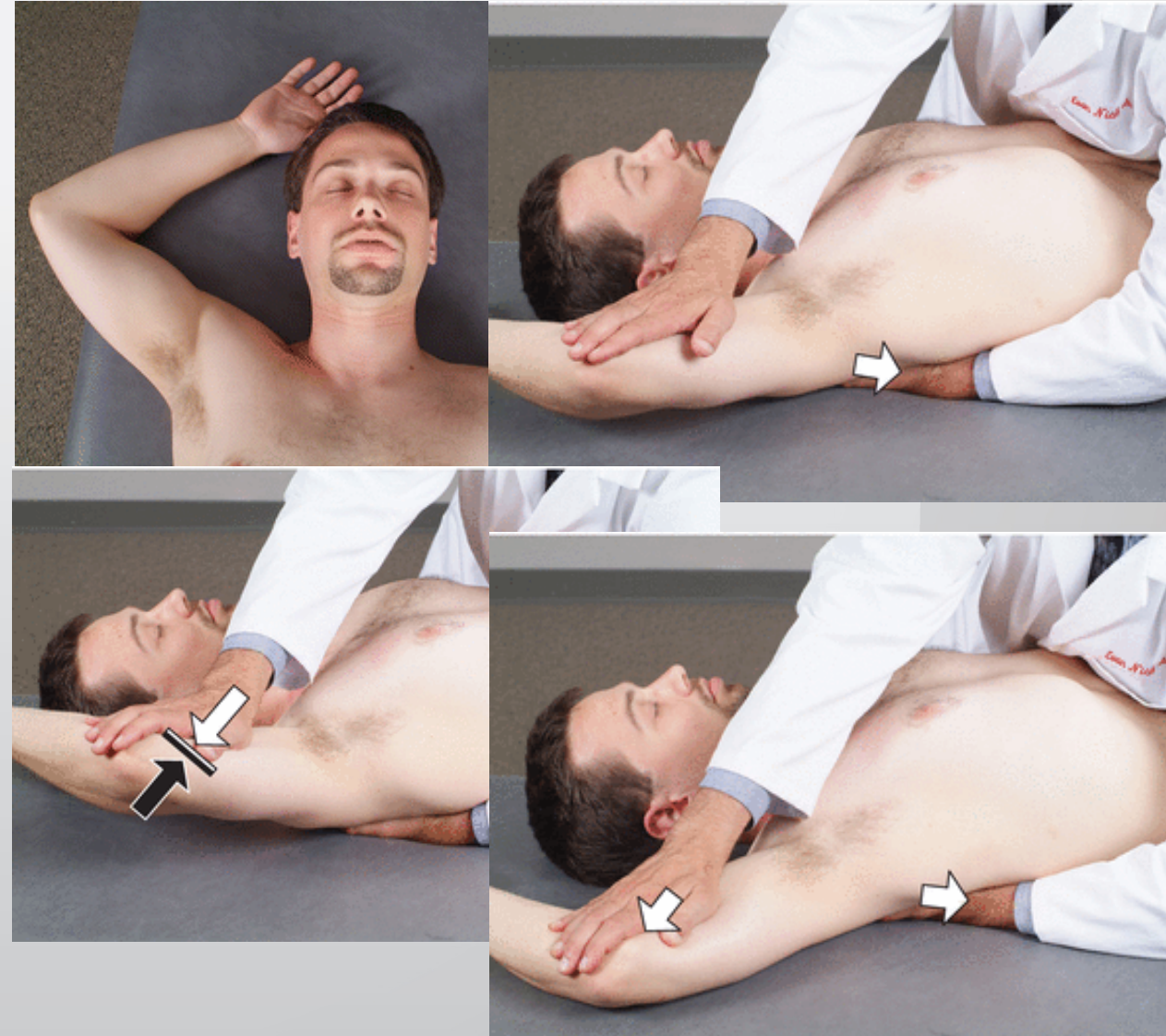Rib 3—Rib 5 Exhalation Dysfunctions

Pectoralis Minor Contraction Mobilizes Rib

Ex: Right Rib 3 Exhaled (Depressed)

1. Patient supine, DO stands at left side of table
2. Patient raises right arm, places hand over head
3. DO's left hand reaches under patient's right side, grasps superior angle of dysfunctional rib, exerts caudad & lateral traction
4. DO's right hand placed over patient's right anterior elbow
5. DO instructs patient to push elbow against DO's right hand as DO applies unyielding counterforce (may ask patient to slowly inhale during contraction to enhance technique effectiveness)
6. Hold isometric contraction 3 to 5 seconds, then instruct patient to *stop and relax*
7. Once patient has completely relaxed, DO's left hand exerts increased caudad & lateral traction on dysfunctional rib angle
8. Steps 5 to 7 are repeated five to seven times or until motion is maximally improved at the dysfunctional rib
9. Reevaluate motion of dysfunctional rib to assess technique effectiveness

Modification: Patient seated on exam table or seated in a chair



Rib Pain

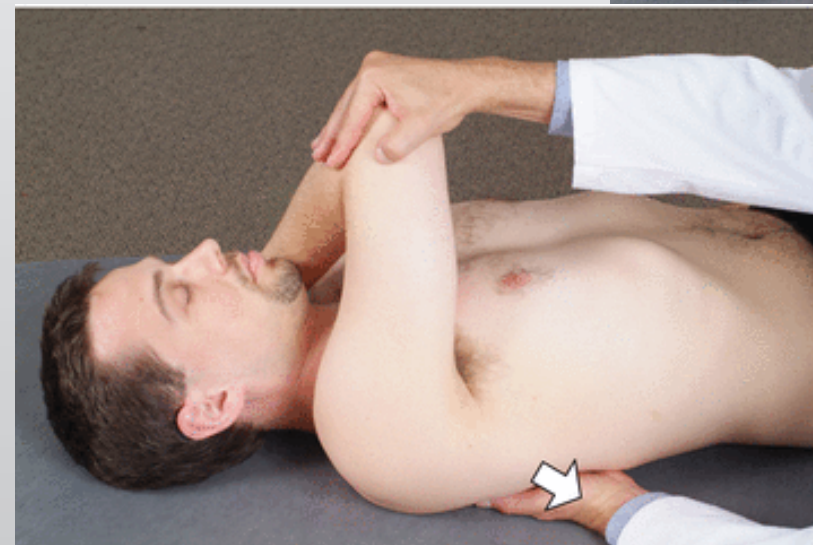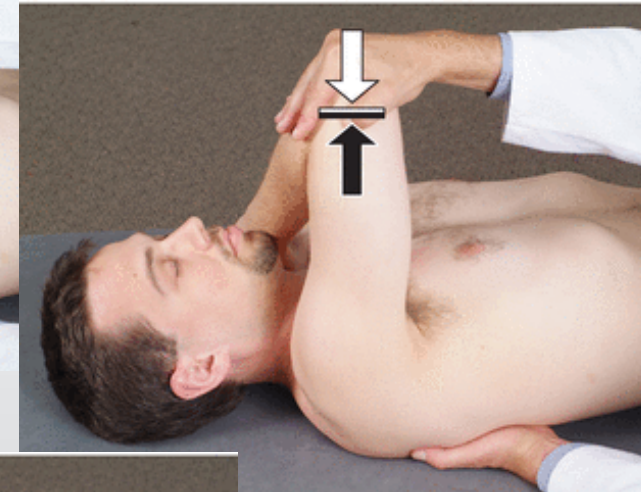
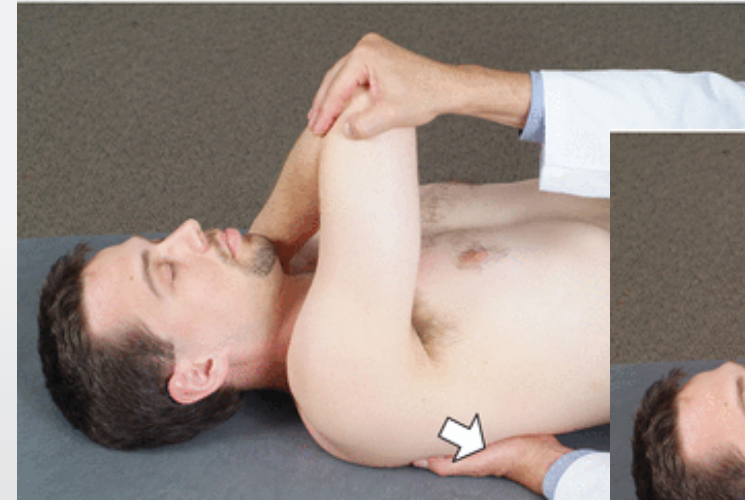
Rib 6—Rib 8 Exhalation Dysfunctions

Serratus Anterior Contraction Mobilizes Rib

Ex: Right Rib 6 Exhaled (Depressed)

1. Patient supine, DO stands/sits at dysfunctional side
2. Flex patient's right shoulder 90 degrees (elbow may be flexed for better control by DO)
3. DO's left hand reaches under patient's right side, grasps superior angle of dysfunctional rib, exerts caudad & lateral traction
4. DO instructs patient to push elbow toward the ceiling (scapular protraction), as DO applies unyielding counterforce (may ask patient to slowly inhale during contraction to enhance technique effectiveness)
5. Hold isometric contraction 3 to 5 seconds, then instruct patient to *stop and relax*
6. Once patient has completely relaxed, DO's left hand exerts increased caudad & lateral traction on dysfunctional rib angle
7. Steps 4 to 6 are repeated five to seven times or until motion is maximally improved at the dysfunctional rib
8. Reevaluate motion of dysfunctional rib to assess technique effectiveness

Modification: Patient seated on exam table or seated in a chair



Rib Pain

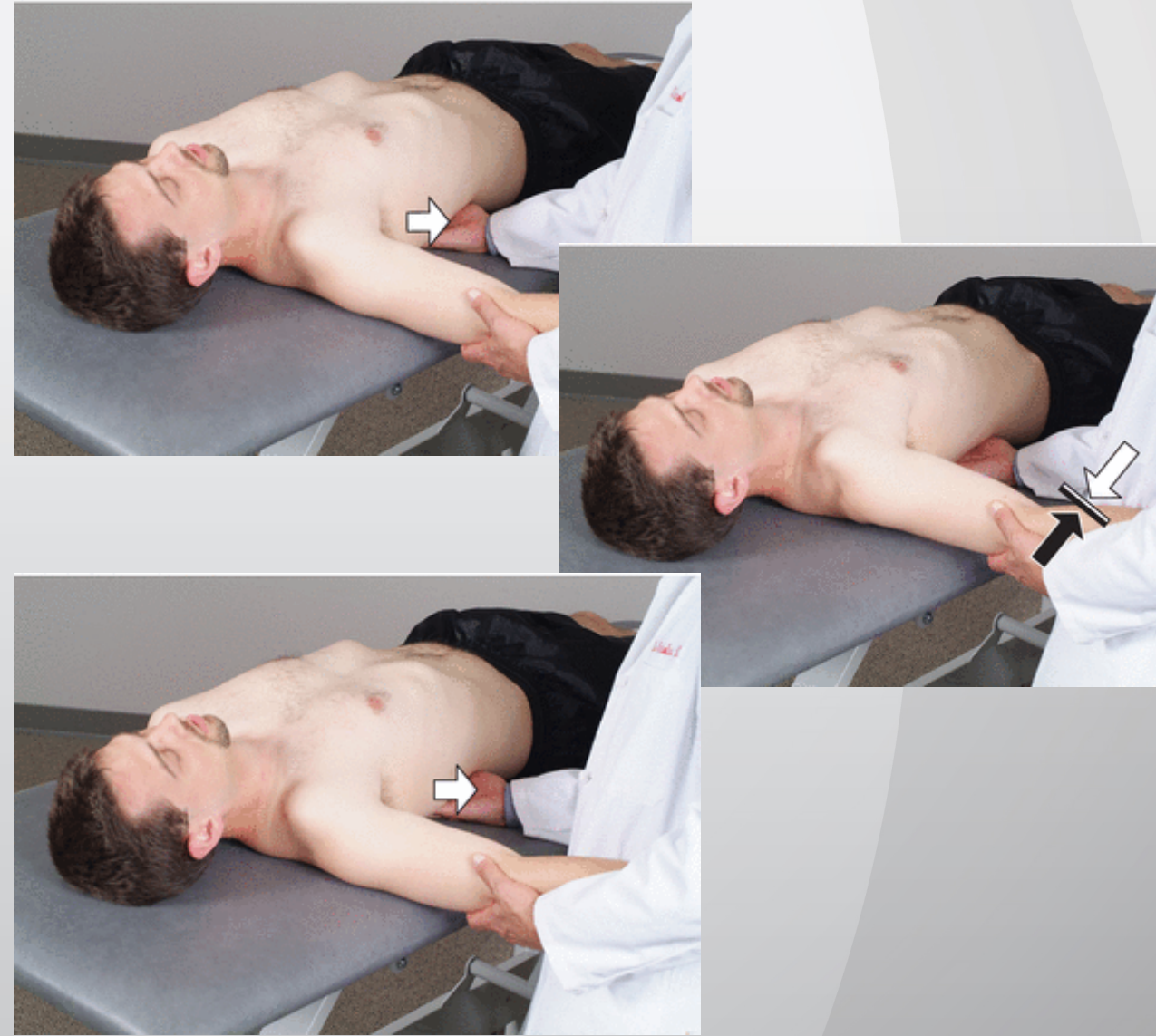Rib 9, Rib 10 Exhalation Dysfunctions

Latissimus Dorsi Contraction Mobilizes Rib

Ex: Right Rib 10 Exhaled (Depressed)

1. Patient supine, DO stands/sits at dysfunctional side
2. DO's left hand abducts patient's right shoulder 90 degrees, DO's right hand reaches under patient, grasps superior angle of the dysfunctional rib, exerting caudad & lateral traction
3. DO's left lateral thigh/knee placed against patient's right elbow
4. DO instructs patient to push right arm into DO's thigh while DO's left thigh or arm applies unyielding counterforce (may ask patient to slowly inhale during contraction to enhance technique effectiveness)
5. Hold isometric contraction 3 to 5 seconds, then instruct patient to *stop and relax*
6. Once patient has completely relaxed, DO's right hand exerts increased caudad & lateral traction on dysfunctional rib angle
7. Steps 4 to 6 are repeated five to seven times or until motion is maximally improved at the dysfunctional rib
8. Reevaluate motion of dysfunctional rib to assess technique effectiveness

Modification: Patient seated on exam table or seated in a chair

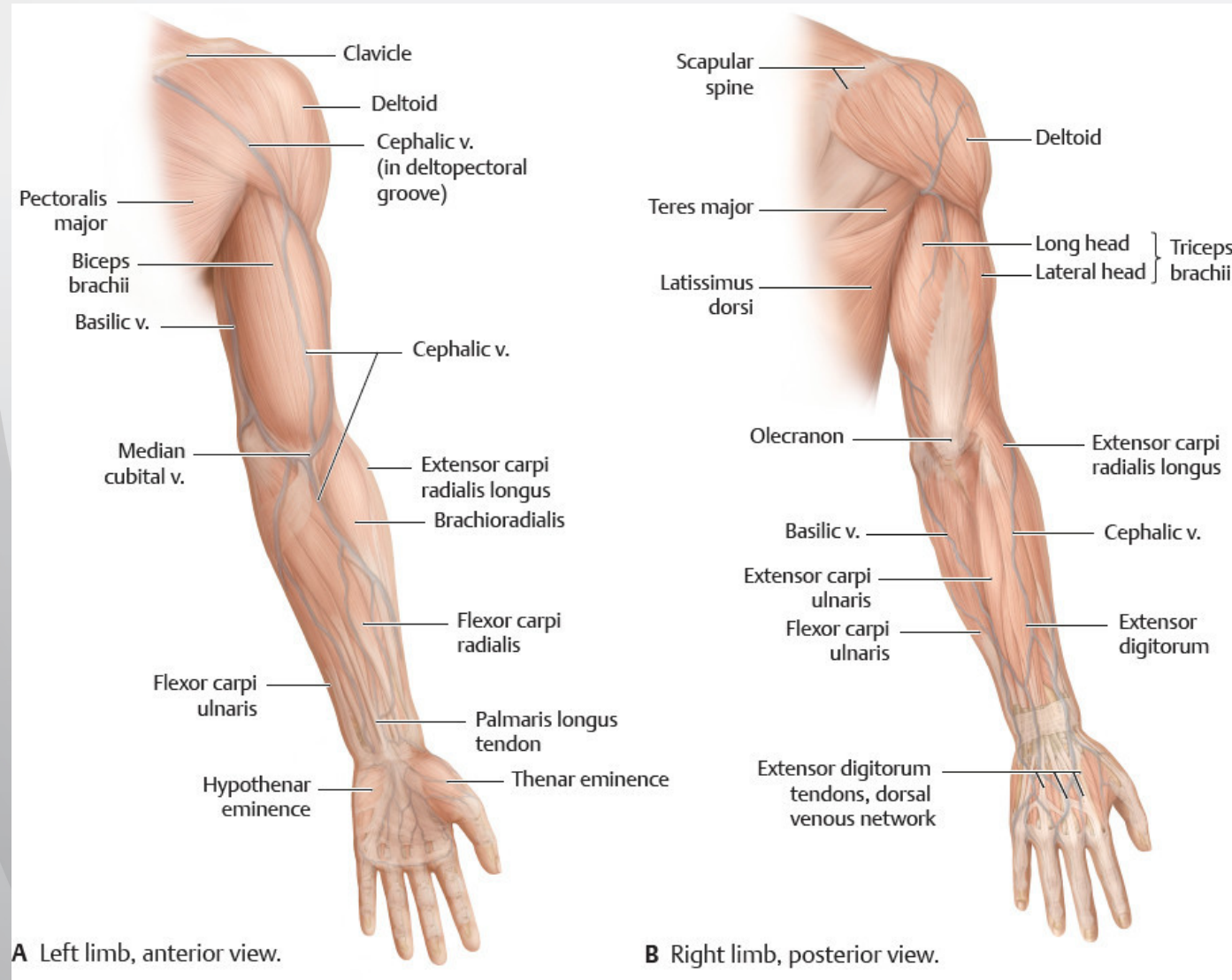


Rib Pain

Contraindications to OMT

- Relative:
 - Acute (moderate to severe) sprain or strain
 - Severe osteoporosis/-penia (DO believes risk of tendinous evulsion occurring with correction)
 - Infection (e.g. osteomyelitis), contagious skin disease, painful rashes/abscesses, acute fasciitis, any other conditions that would preclude skin contact; severe illness (i.e. postsurgical/ICU patient)
- Absolute:
 - Fracture, dislocation, or moderate to severe joint instability at treatment site
 - Lack of patient cooperation/comprehension of the instructions of the technique (i.e., infant or young child or patient who does not understand the physician's language)
 - Patient refusal of treatment (at any time)

Sport-Related Extremity Injury



- Acute or sub-acute
- Achy, soreness, tenderness in muscle/tendon
- +/- reduced range of motion
- Exacerbated by activity, especially w/sport
- Incidental; physician finds tenderness during routine sports physical

Sport-Related Extremity Injury

Potential pitfalls in the urgent care setting

- More severe pathology
 - Identify/rule out red flags
 - Fall or trauma → fracture
 - Special tests for instability = positive → ligament tear
 - Tense extremity, decreased distal pulses → compartment syndrome
 - Erythematous, swollen, tender calf, unilateral → DVT
- Time constraints
 - Problem: It takes time to obtain proper informed consent for OMT
 - Solution: It usually takes just a few minutes to explain the risks, benefits and alternatives for OMT. The more you practice your script, the more efficient it will become. Additionally, consider creating an informational pamphlet about OMT (or order pre-printed ones from the AOA) to have in the waiting room so that interested patients may “pre-read” about OMT.

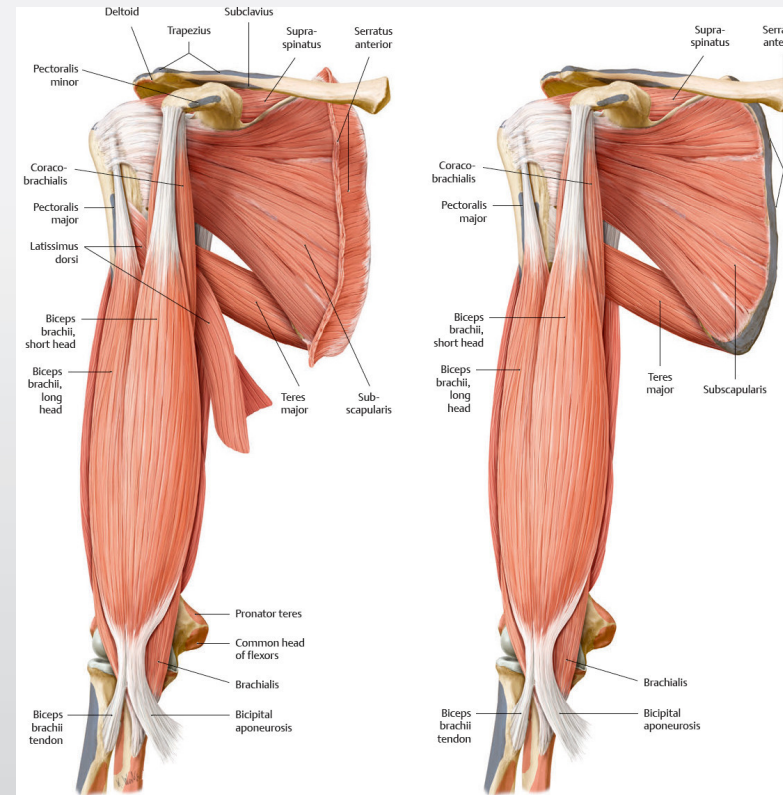
Sport-Related Extremity Injury

- If no red flags present, move on to Osteopathic Structural Exam (OSE)

- Upper Extremity: AROM, PROM, palpatory exam (GH joint, AC joint, clavicle, elbow, radial head, carpal bones)

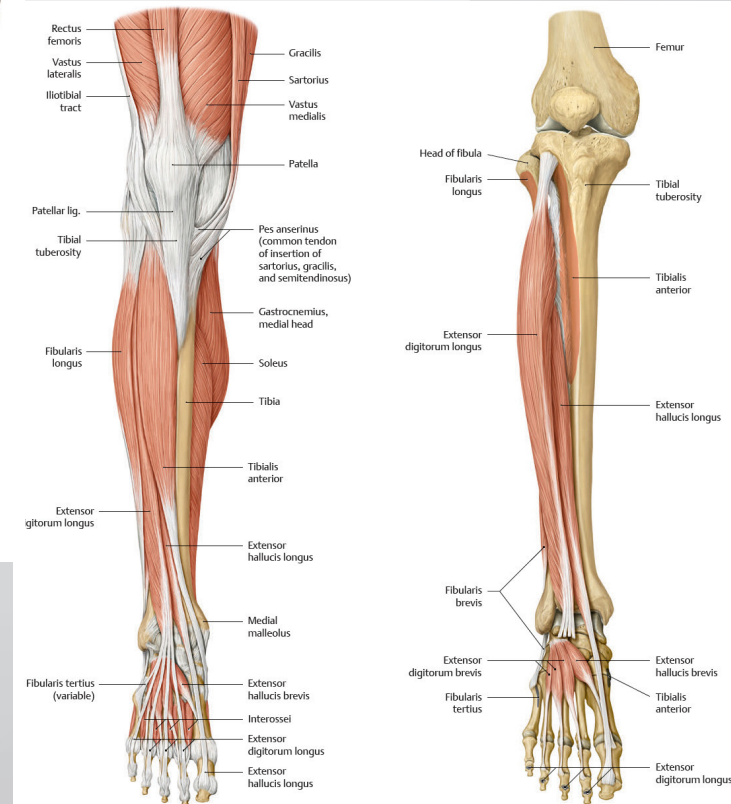
- Lower Extremity: AROM, PROM, palpatory exam (hip, knee, fibular head, ankle, foot)

- Consider weight-bearing exam and gait evaluation as part of LE evaluation



A Removed: Thoracic skeleton. Partially removed: Latissimus dorsi and serratus anterior.

B Removed: Latissimus dorsi and serratus anterior.



A All muscles shown.

B Removed: Tibialis anterior and fibularis longus; extensor digitorum longus tendons (distal portions). Note: The fibularis tertius is a division of the extensor digitorum longus.

Sport-Related Extremity Injury

Upper Extremity

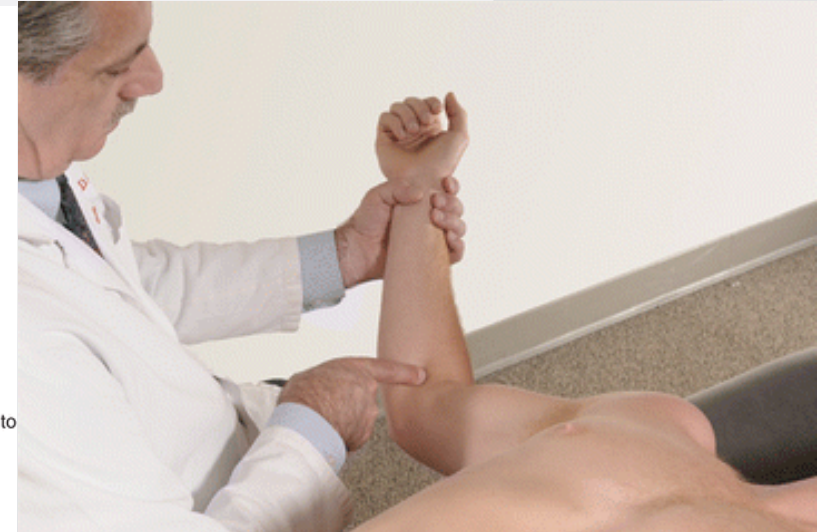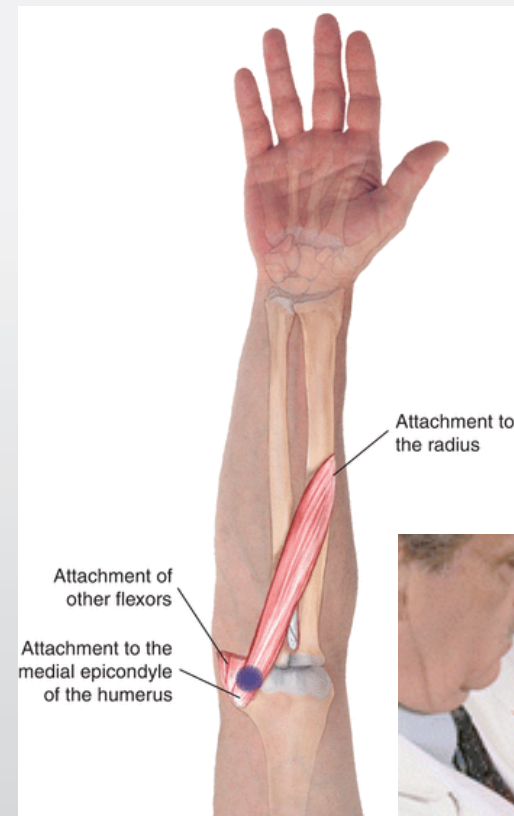
Medial Epicondyle (Pronator Teres)

Indications for Treatment: SD of the UE. Patient may complain of pain in the anterior medial aspect of the elbow near the medial epicondyle.

Tender Point Location: At or near the medial epicondyle of the humerus associated with common flexor tendon and attachment of the pronator teres muscle.

Treatment Position: F PRO Add

1. Patient supine, DO sits/stands on side of tender point
2. Patient's elbow flexed, wrist markedly pronated, and forearm slightly adducted
3. DO fine-tunes (more or less elbow flexion, wrist pronation, & forearm adduction) until tenderness is *completely alleviated* or reduced as close to 100% as possible, but at least 70%



Sport-Related Extremity Injury

Lower Extremity

Lateral Meniscus

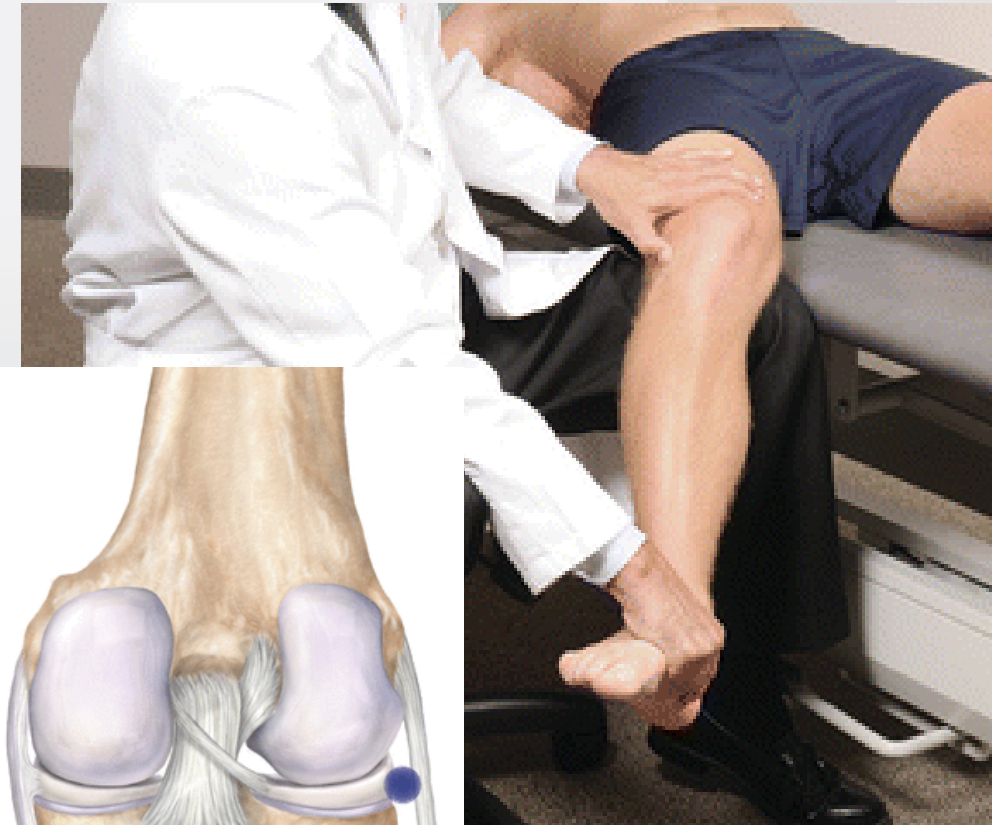Lateral (Fibular) Collateral Ligament

Indications for Treatment: SD of the LE. Patient may present with pain along lateral aspect of the knee associated with sprain of the fibular (lateral) collateral ligament and/or inflammation of the lateral meniscus.

Tender Point Location: One the lateral aspect of the knee at the lateral joint line associated with fibular (lateral) collateral ligament & lateral meniscus.

Treatment Position: F Abd ir/er

1. Patient supine, DO sits/stands on side of tender point
2. Patient's hip/thigh abducted so leg hangs off edge of the table
3. DO grasps patient's lateral ankle/foot to control the lower leg
4. Patient's knee flexed approximately 35 to 40 degrees with slight abduction & internal or external rotation of the tibia (may require ankle dorsiflexion & eversion)
5. DO fine-tunes (more or less flexion, abduction, and internal or external rotation) until tenderness is *completely alleviated* or reduced as close to 100% as possible, but at least 70%.



Sport-Related Extremity Injury

Contraindications to OMT

- Relative:
 - Cannot understand instructions/questions (e.g., 6 month-old) or voluntarily relax (difficult positioning)
 - Cannot discern pain level or change w/positioning
 - Patients in whom positioning for tender point pain reduction exacerbates a distal connective tissue/arthritis problem or no motion available for positioning (e.g., connective tissue disease, arthritis, Parkinson disease, etc.)
- Absolute:
 - Traumatized (sprained or strained) tissues, which would be negatively affected by the positioning of the patient
 - Severe illness w/strict positional restrictions precluding treatment
 - Instability w/potential to produce unwanted neuro/vascular side effects
 - Vascular or neurologic syndromes (e.g. basilar insufficiency, neuroforaminal compromise) whereby treatment position could exacerbate the condition
 - Severe degenerative spondylosis w/local fusion & no motion at level where tx positioning would occur
 - Patient refusal of treatment (at any time)

The Next Step

Patient follow-up visit(s)

1. You (urgent care clinic)
2. You (PCP, OMM/specialty)
3. Neuromusculoskeletal Medicine (OMM/NMM) specialist

Find an OMT provider:

- American Osteopathic Association (AOA)
 - <https://doctorsthatdo.org/>
- American Academy of Osteopathy (AAO)
 - <http://www.academyofosteopathy.org/find-an-osteopathic-physician>
- The Osteopathic Cranial Academy (OCA)
 - <https://cranialacademy.org/find-a-physician/>
- Your state osteopathic medical society
 - Example: California
<https://www.opsc.org/search/custom.asp?id=2062>

References

- Nicholas A, Nicholas E. Atlas of Osteopathic Techniques. 3rd Edition. Wolters Kluwer; 2016.
- Slide 5: Osteopathic Billing & Coding. <https://osteopathic.org/practicing-medicine/business-of-medicine/osteopathic-billing-coding/>.
- Slide 6: Snider KT, Jorgensen DJ. Billing and Coding for Osteopathic Manipulative Treatment [published correction appears in *J Am Osteopath Assoc*. 2009;109:574]. *J Am Osteopath Assoc*. 2009;109:409-413. <https://jaoa.org/article.aspx?articleid=2093843>. Accessed September 24, 2019.
- Slide 7: OMT Coding Instructional Manual. 2nd Edition. American Osteopathic Association; 2013.

Photo Credits

- Slide 3: <https://www.consumerreports.org/health-clinics/urgent-care-or-walk-in-health-clinic/>
- Slide 4: <https://doctorsthatdo.org/difference>
- Slide 8: [Head & Neck](#). In: [Gilroy A](#), [MacPherson B](#), [Schünke M](#), et al., ed. [Atlas of Anatomy](#). 3rd Edition. Thieme; 2016. doi:10.1055/b-005-148856
- Slide 9: [14.2 Painful Syndromes of the Head and Neck](#). In: [Mattle H](#), [Mumenthaler M](#), [Taub E](#), ed. [Fundamentals of Neurology: An Illustrated Guide](#). 2nd Edition. Thieme; 2017. doi:10.1055/b-005-148890
- Slide 11: [Muscles of the Back: Overview](#). In: [Gilroy A](#), [MacPherson B](#), [Schünke M](#) et al., ed. [Atlas of Anatomy](#). 3rd Edition. Thieme; 2016. doi:10.1055/b-005-148856
- Slides 12-13: Soft Tissue Techniques. In: Nicholas A, Nicholas E. Atlas of Osteopathic Techniques. 3rd Edition. Wolters Kluwer; 2016.
- Slide 15: Bones of the thorax, anterior view. From: Thoracic Region. In: Seffinger MA, ed. Foundations of Osteopathic Medicine: Philosophy, Science, Clinical Applications, and Research. 4th Edition. Wolters Kluwer; 2018.
- Slide 17: [Thorax](#). In: [Gilroy A](#), [MacPherson B](#), [Schünke M](#), et al., ed. [Atlas of Anatomy](#). 3rd Edition. Thieme; 2016. doi:10.1055/b-005-148856
- Slides 18-21: Muscle Energy Techniques. In: Nicholas A, Nicholas E. Atlas of Osteopathic Techniques. 3rd Edition. Wolters Kluwer; 2016.
- Slides 23 & 25: [Upper Limb](#). In: [Gilroy A](#), [MacPherson B](#), [Schünke M](#), et al., ed. [Atlas of Anatomy](#). 3rd Edition. Thieme; 2016. doi:10.1055/b-005-148856
- Slide 25: [Lower Limb](#). In: [Gilroy A](#), [MacPherson B](#), [Schünke M](#), et al., ed. [Atlas of Anatomy](#). 3rd Edition. Thieme; 2016. doi:10.1055/b-005-148856
- Slides 26-29: Counterstrain Techniques. In: Nicholas A, Nicholas E. Atlas of Osteopathic Techniques. 3rd Edition. Wolters Kluwer; 2016.

Contact Information

Michael Conte, D.O.

Assistant Professor of Osteopathic Principles and Practices

California Health Sciences University College of Osteopathic Medicine

mconte@chsu.edu

CHSU

CALIFORNIA

HEALTH SCIENCES

UNIVERSITY